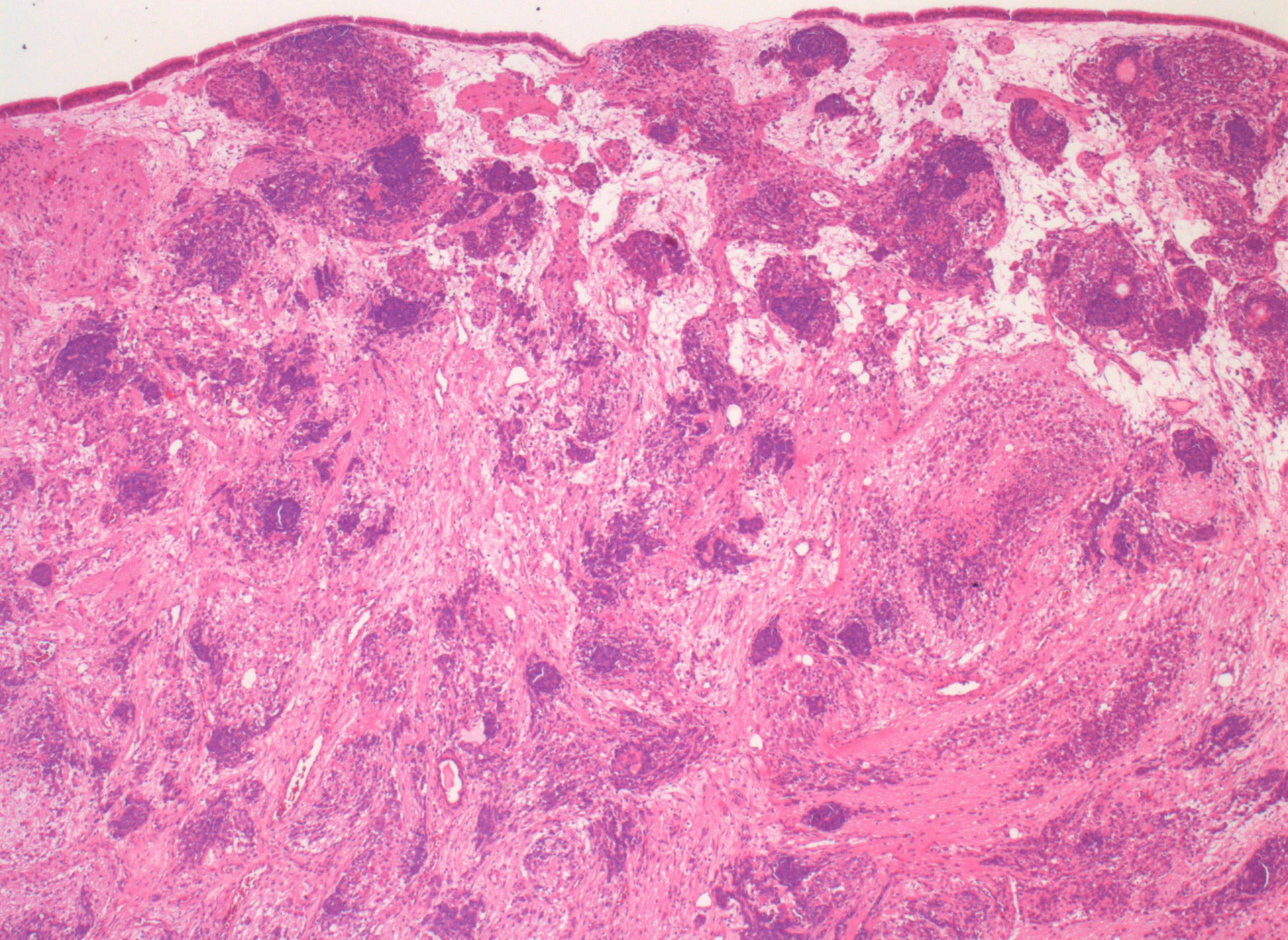


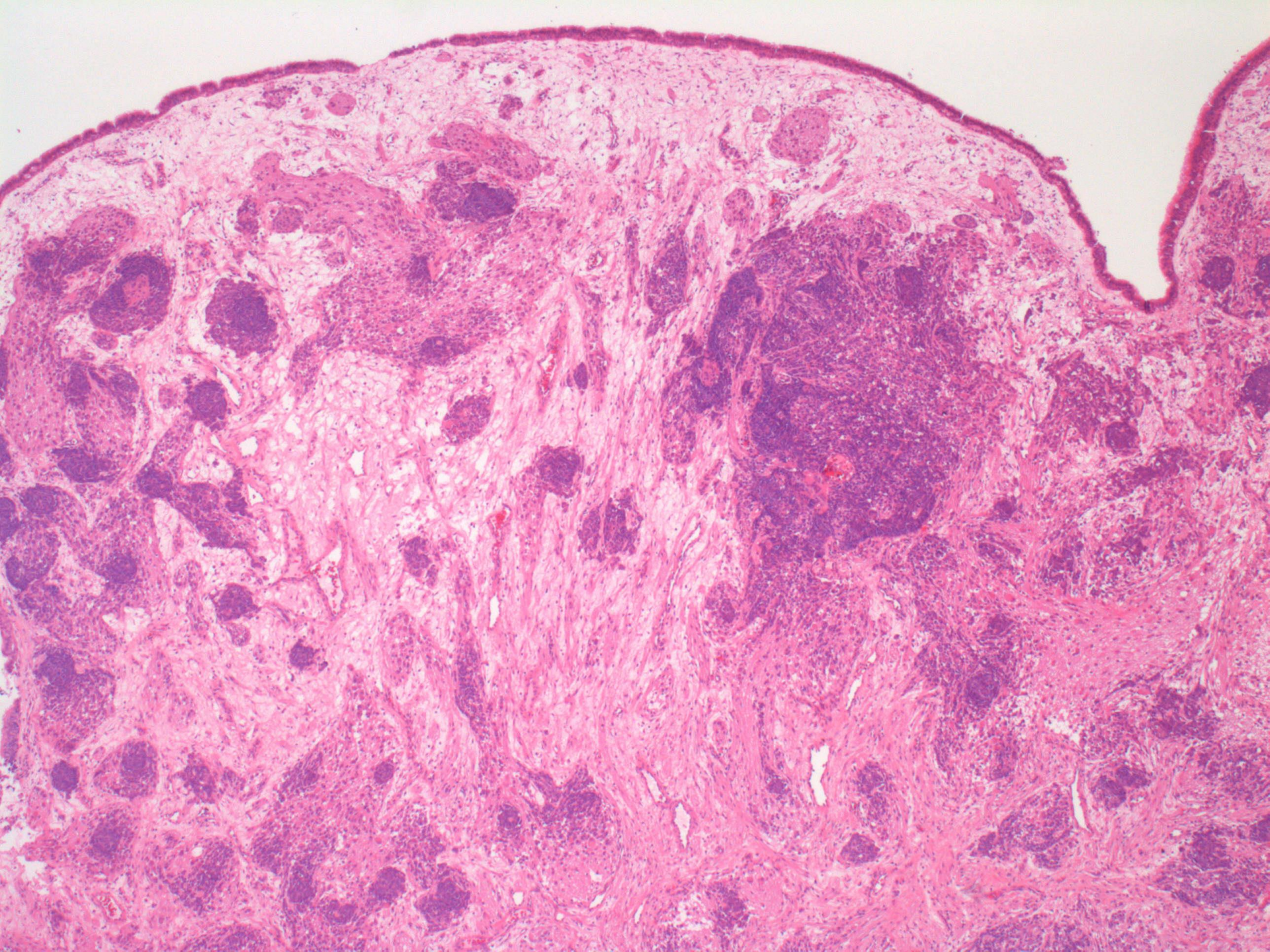
Clinical Summary

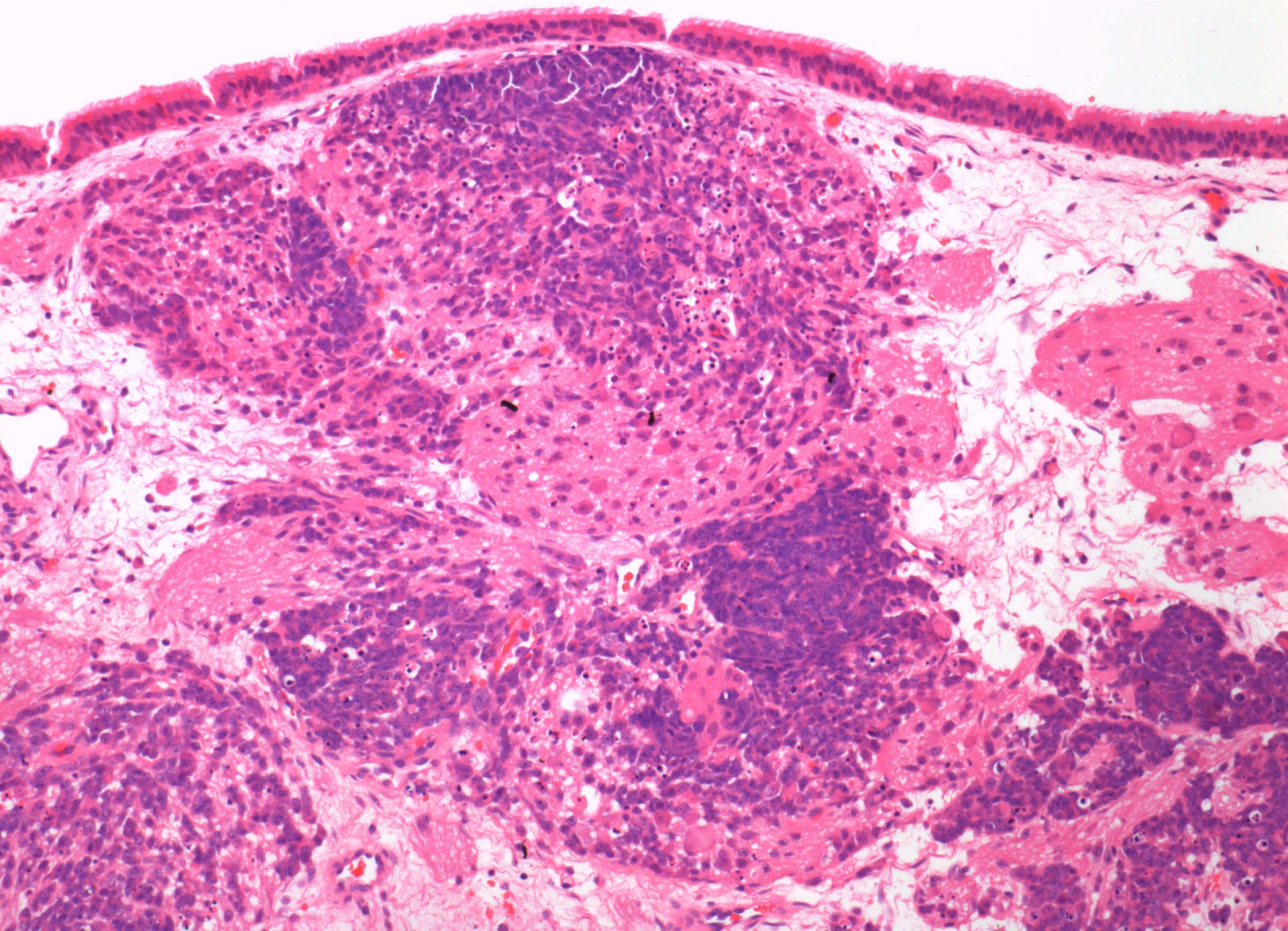
- 38 year old female
- Presented with anosmia April 2013, loss of taste October 2013, medical treatment for CRS, April 2014
- Ct scan unilateral disease listed for FESS biopsy Dec 2014
- FH mother died of cancer at 37, grandmothers at 54 and 56 breast and ovarian respectively.

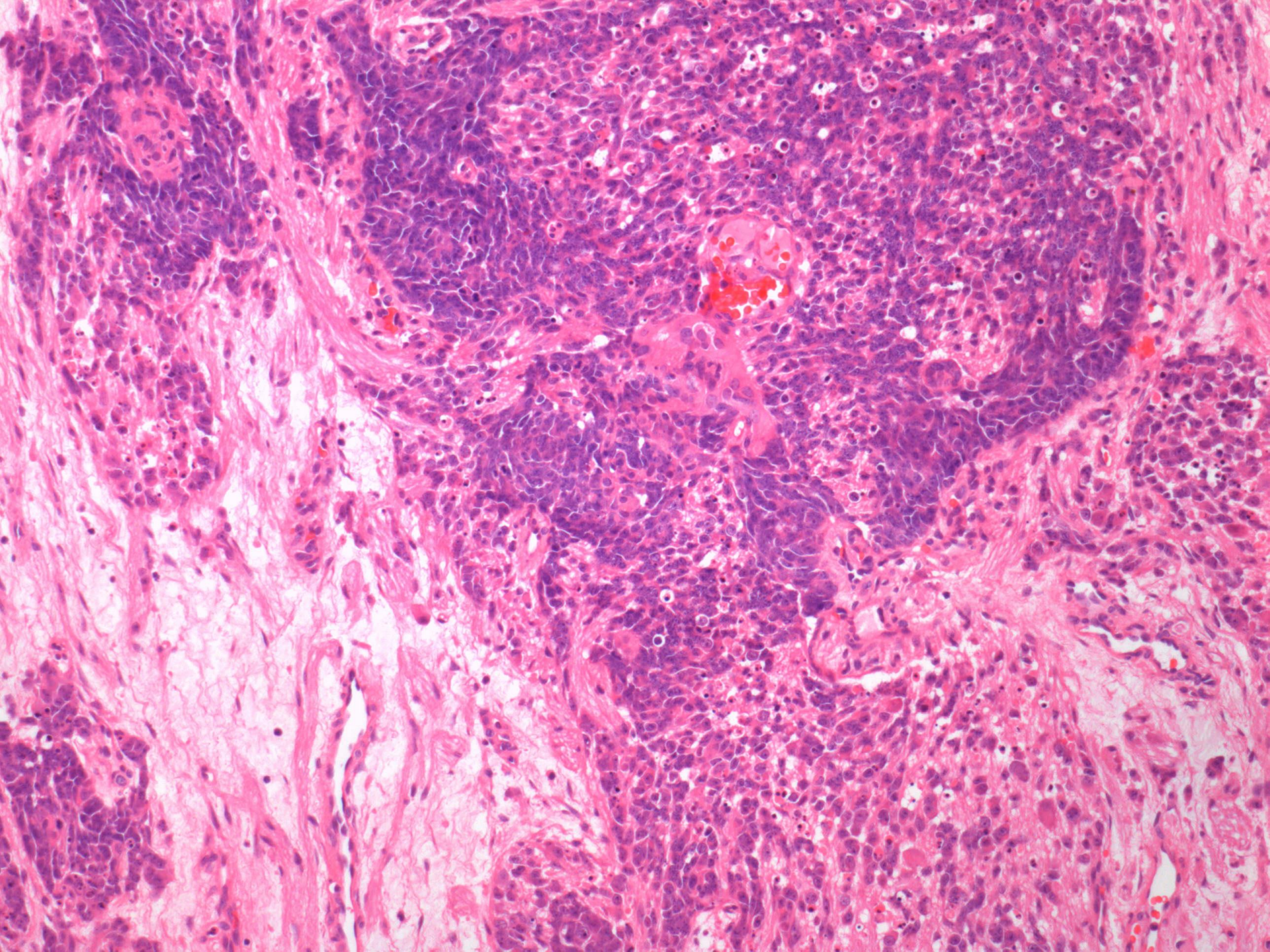
Clinical Findings

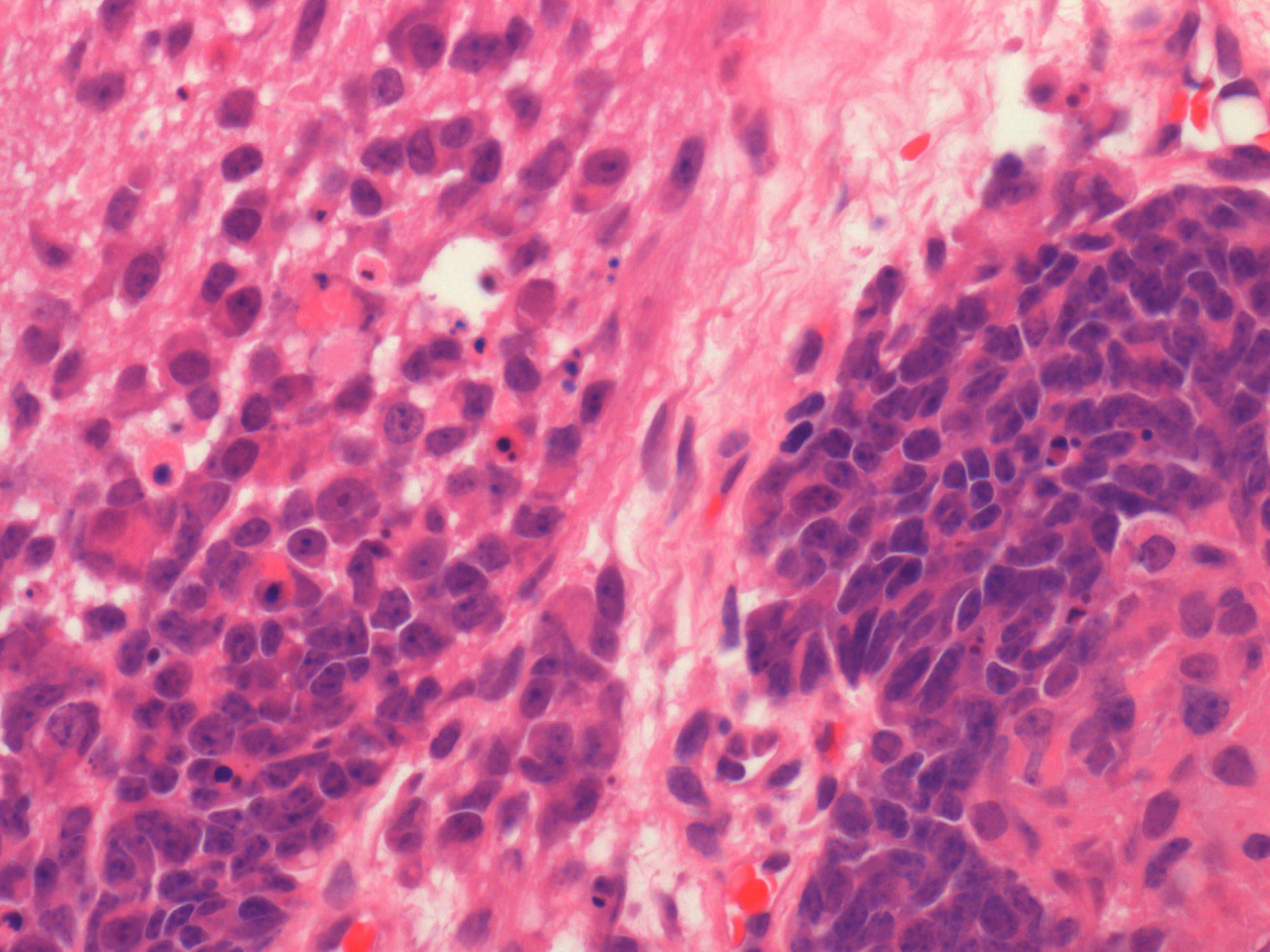
- Normal eye movements no diplopia or proptosis
- Neck NAD
- Botryoid, hanging midline nasal mass

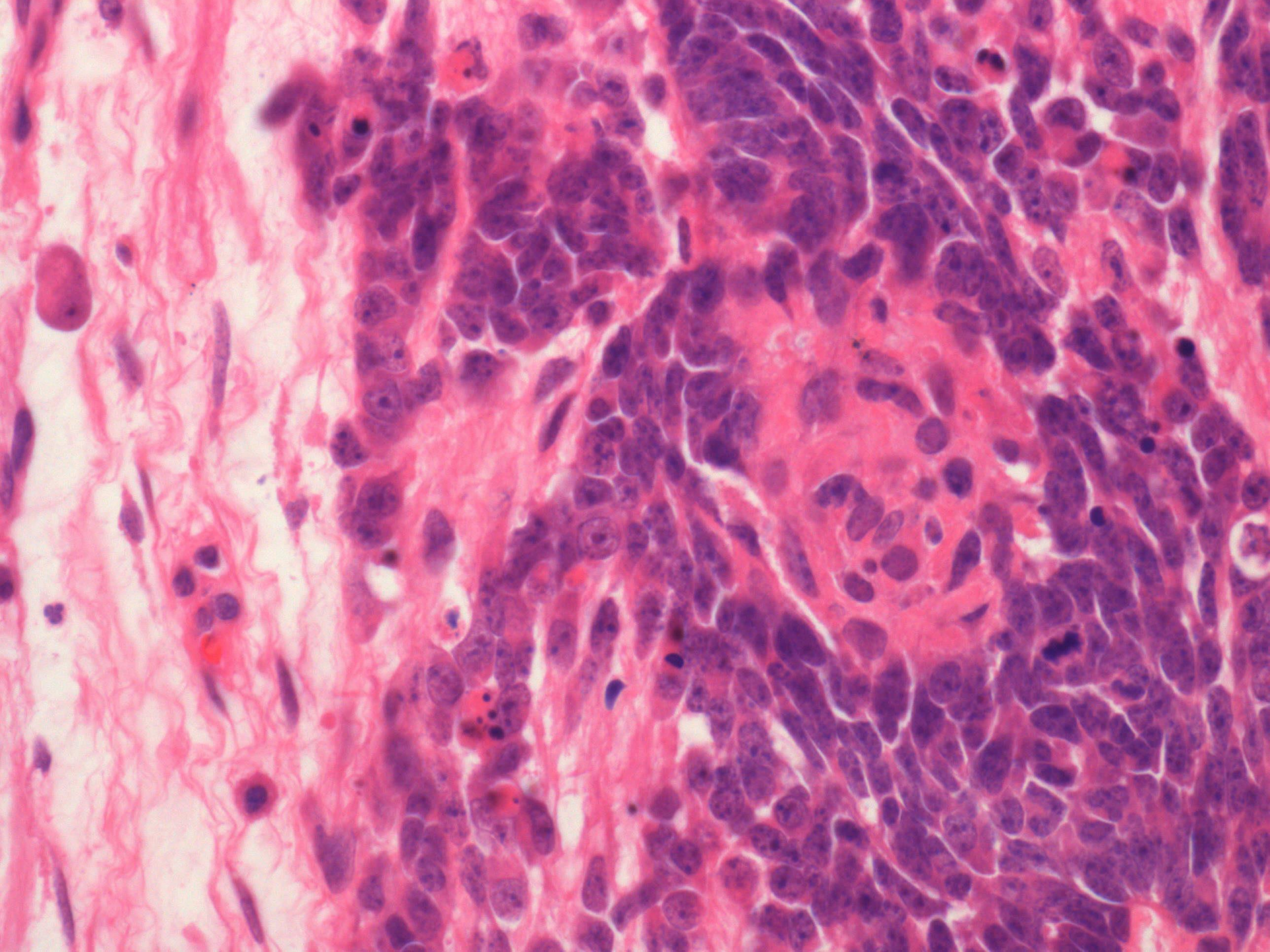


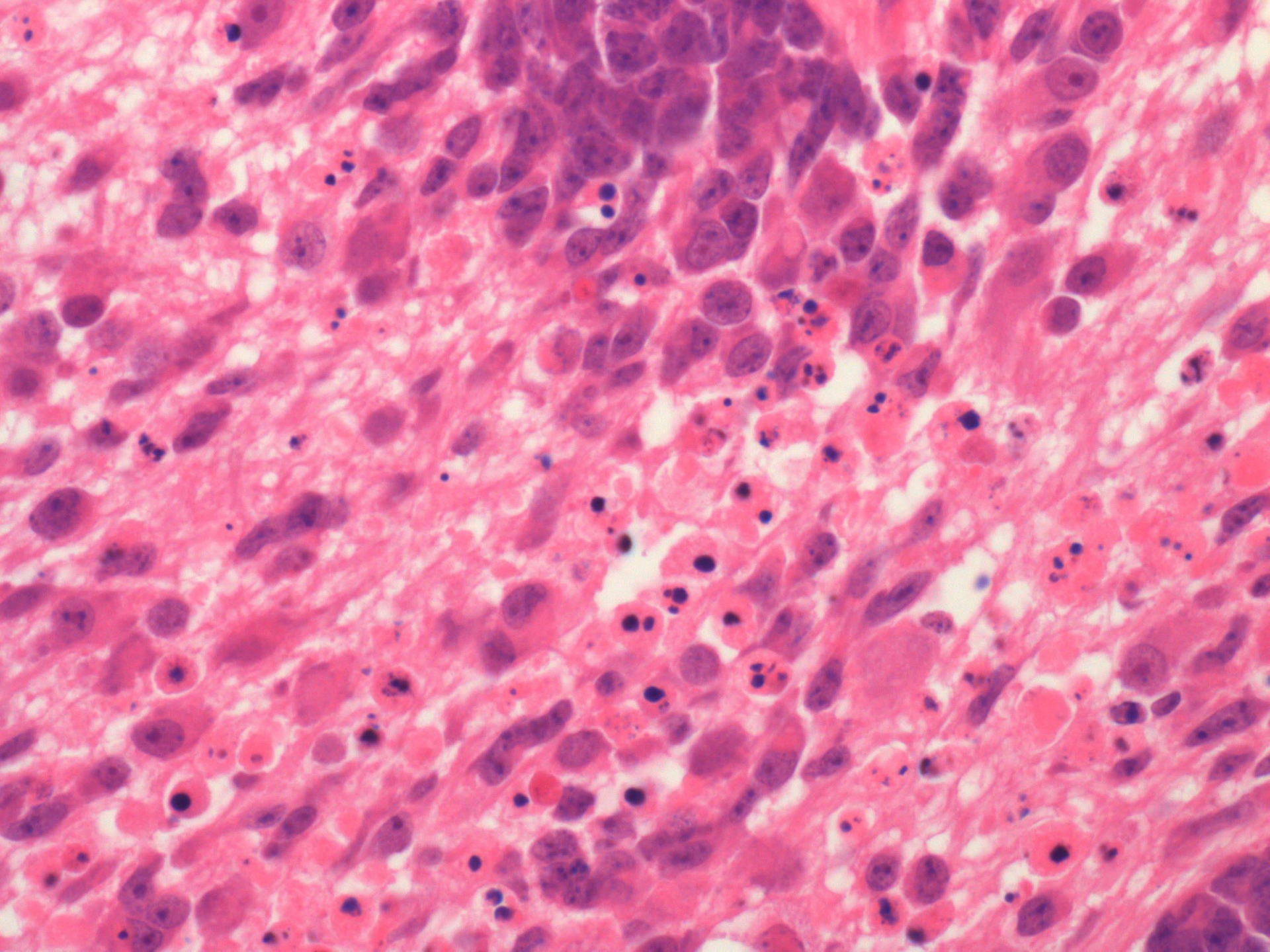


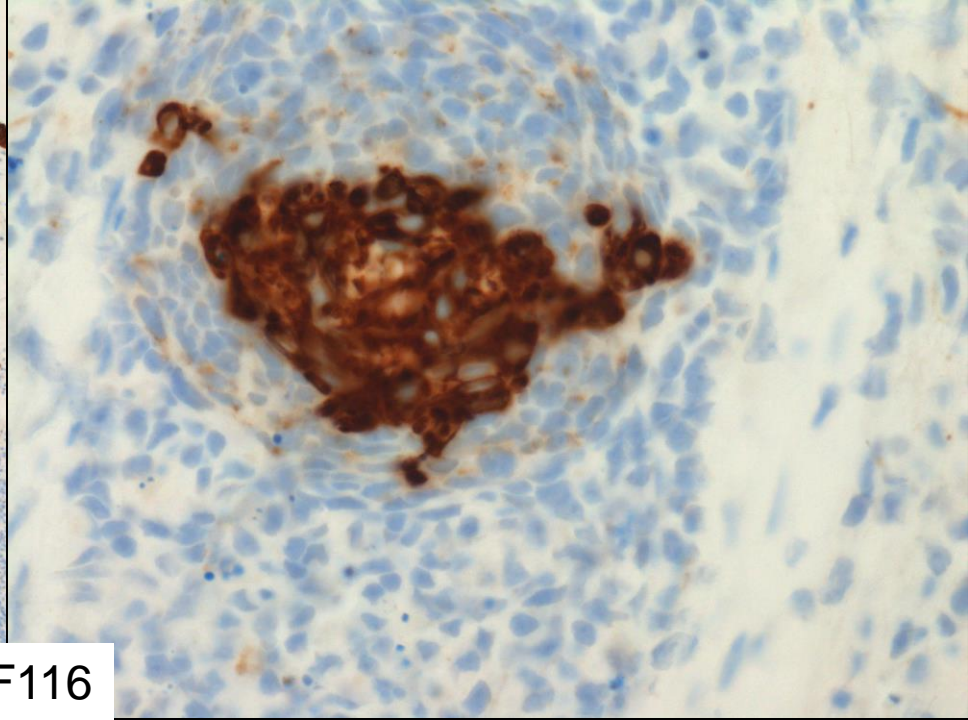
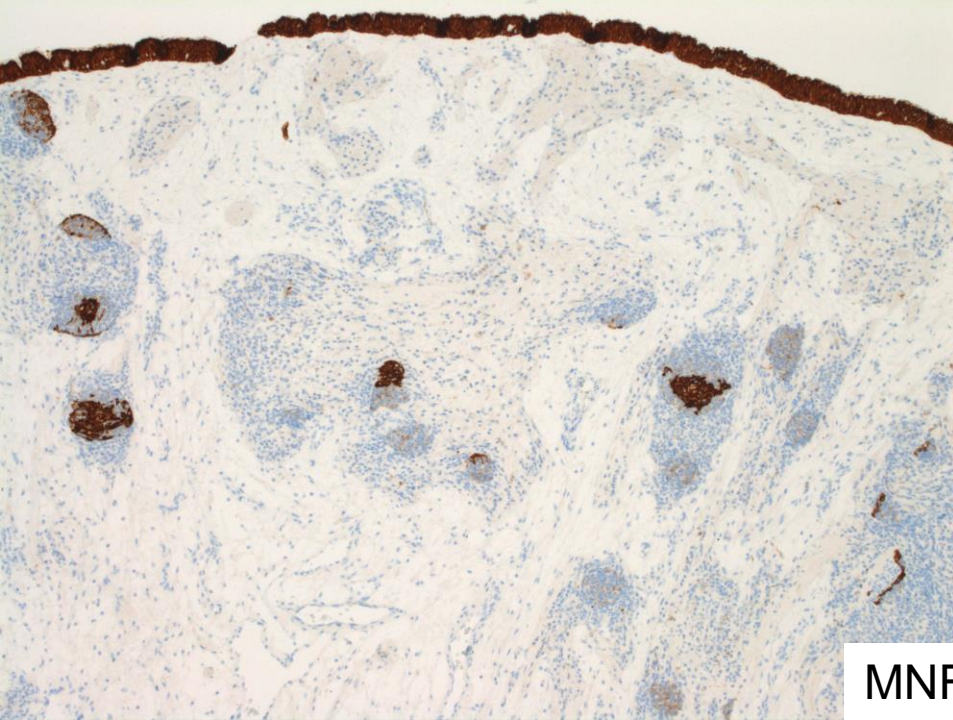




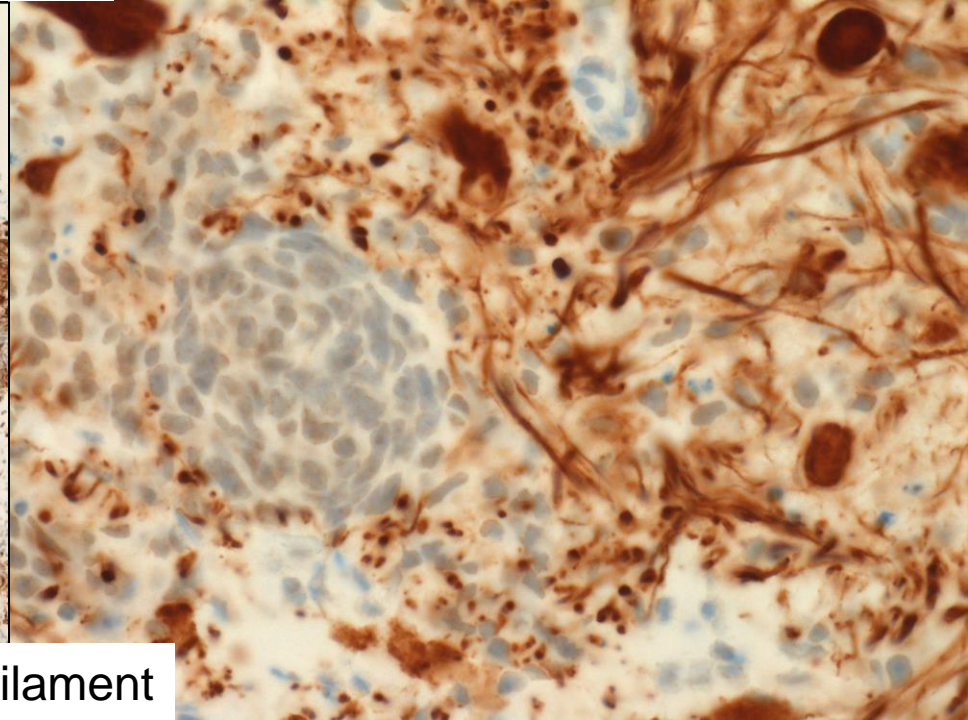
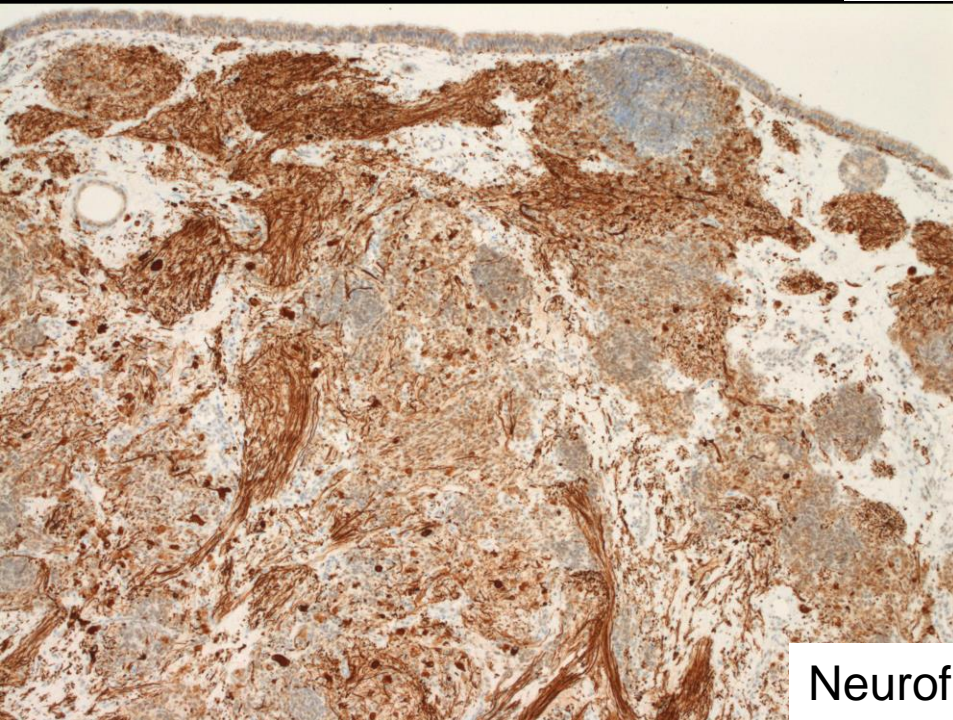








MNF116



Neurofilament

S100

